

FULL ARCH REHABILITATION WITH A COMPLETE DIGITAL WORKFLOW



Martin Wanendeya,
BDS (Bristol) DiplImpDent
DentCS (Eng) Adv. Cert.

Steve Campbell,
RDT Director of Finance at Dental
Laboratories Association (DLA)

Khristo Ivanov,
RDT Uniga Dental
Laboratory

Case information

A 67-year-old male patient presented with moderate to advanced bone loss in the maxilla, resulting in a poor prognosis for many of the existing upper teeth. Treatment options were discussed with the patient, which included partial rehabilitation of the upper arch to retain some of the remaining healthy teeth. This would involve extracting and restoring several teeth with dental implants. The other treatment option was to carry out a full rehabilitation of the upper arch, involving extraction of all the teeth and placement of six dental implants, which would support a screw-retained bridge. Due to sensitivity and the desire for an aesthetic and long-lasting fixed restoration, the patient chose the latter option.

Treatment Planning

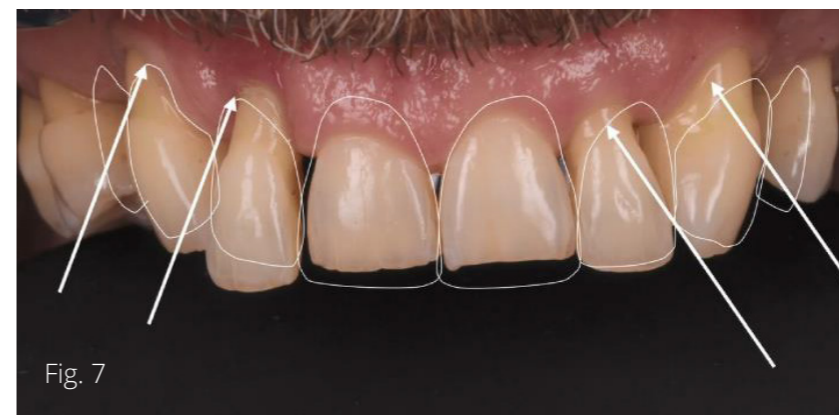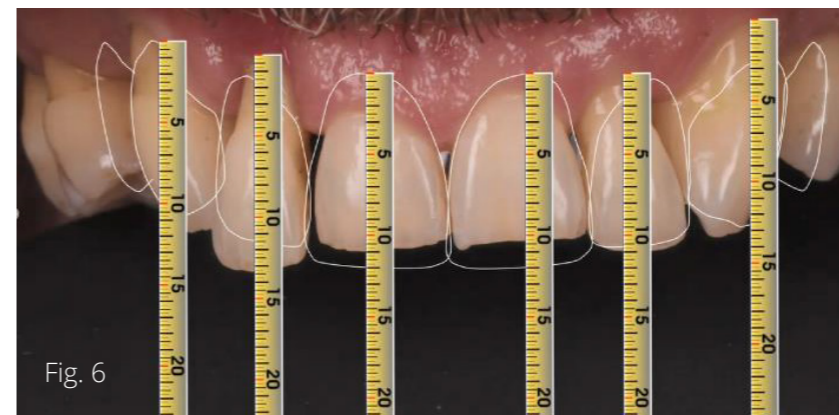
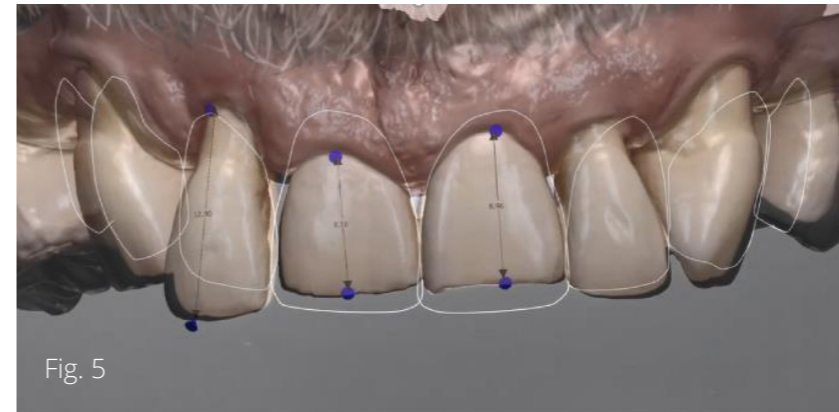

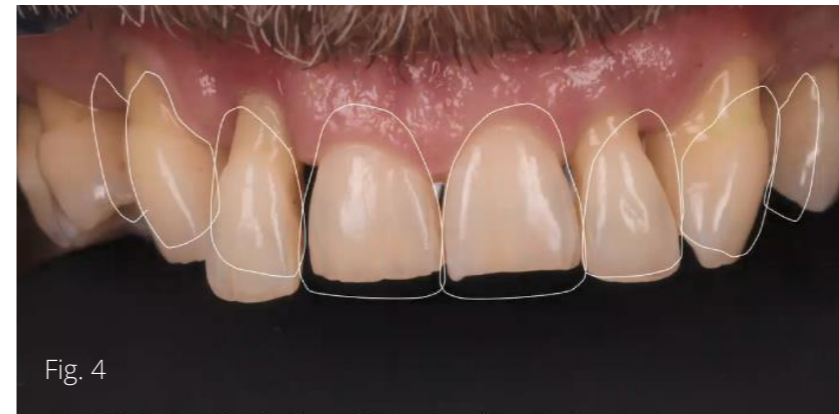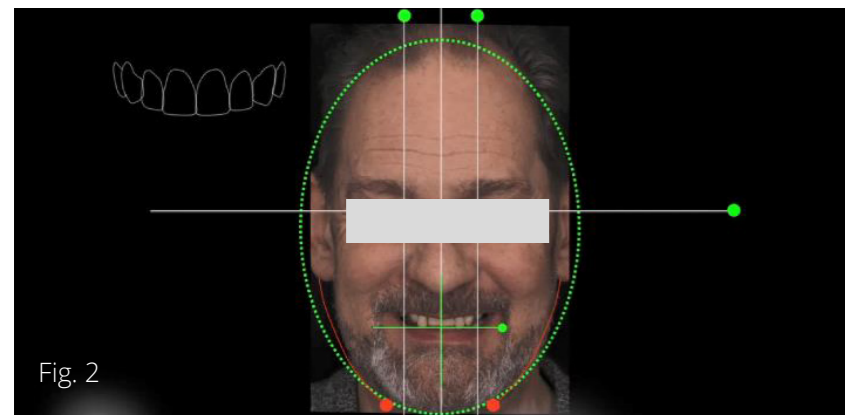
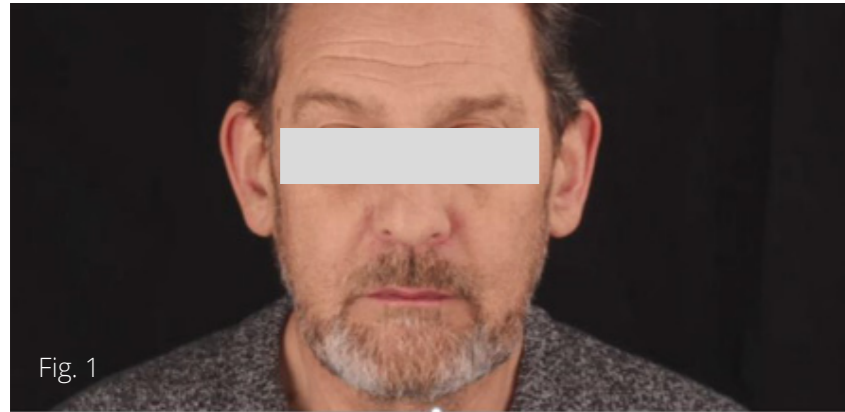The goal was to deliver treatment from beginning to end with a fully digital workflow using various technology and software available.

Elos Accurate® products used in this case:



Fig. 1 - 7

Digital Smile Design (DSD) was used to analyse the patient's face – including his midline and papillary line – create a digital wax-up and design the ideal smile curve. The tooth and soft tissue heights of the proposed restoration were also calculated at this time.



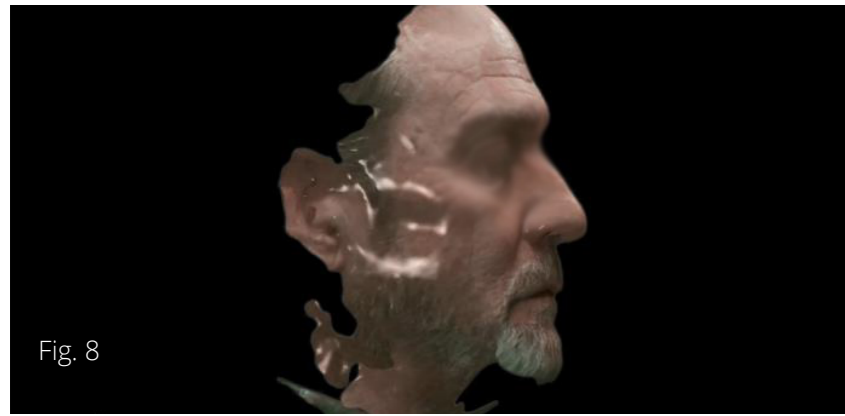


Fig. 8

Fig. 8 - 15
The SNAP face scanner from Degree of Freedom was used to take a 3D scan of the patient's face.

Following this, an intraoral scan of the patient's dentition was taken with the 3Shape TRIOS intraoral scanner and a CBCT image was taken using the GENDEX DP700.

This data was imported into the exocad software and merged together with the digital wax-up.

Combining these layers of data into one image enabled us to plan treatment according to the patient's facial structure.




Fig. 9

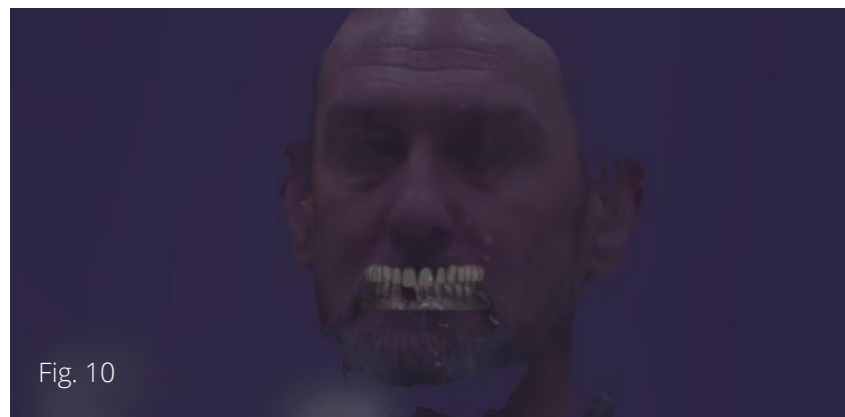


Fig. 10

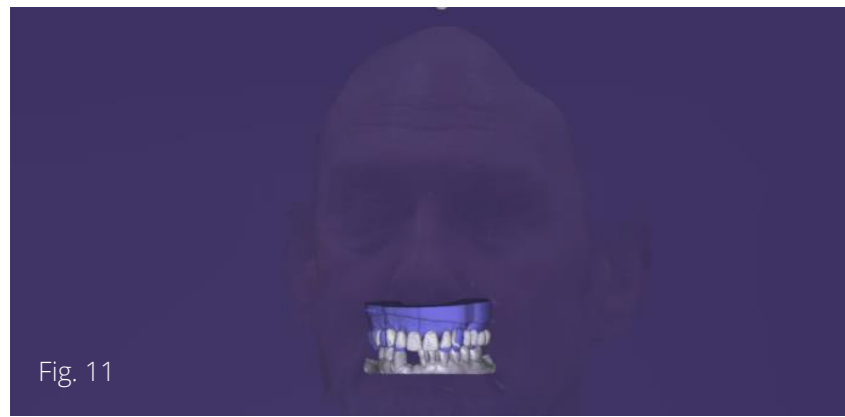
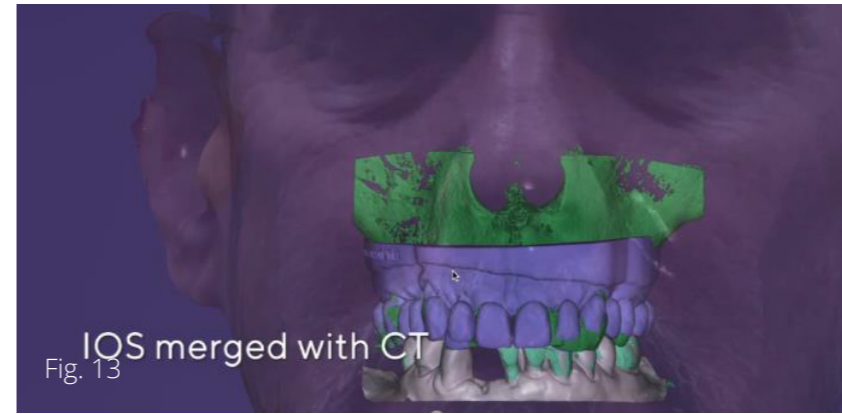


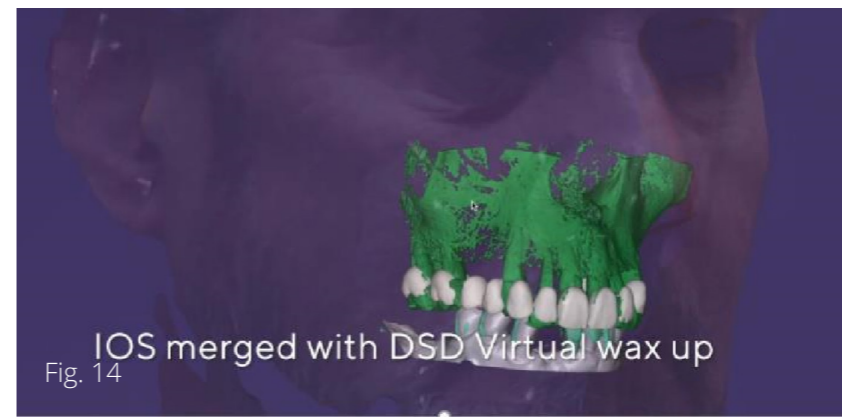
Fig. 11

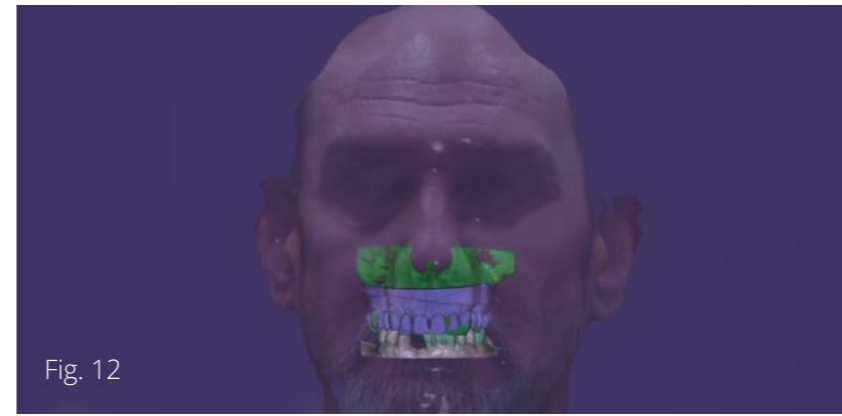

Fig. 12



IOS merged with CT
Fig. 13



IOS merged with DSD Virtual wax up
Fig. 14

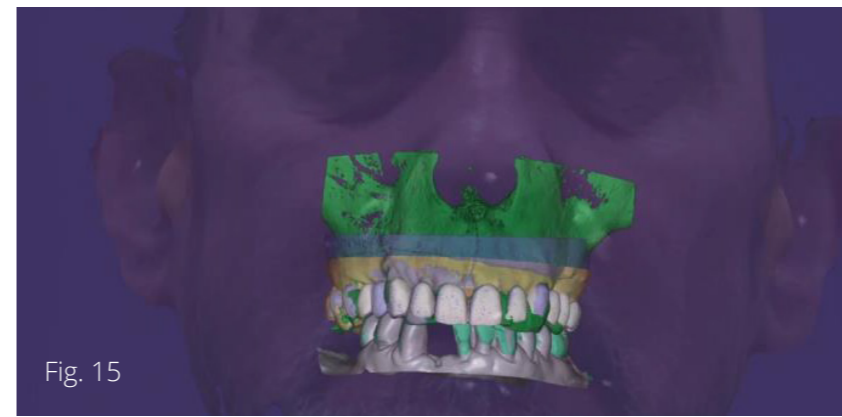


Fig. 15

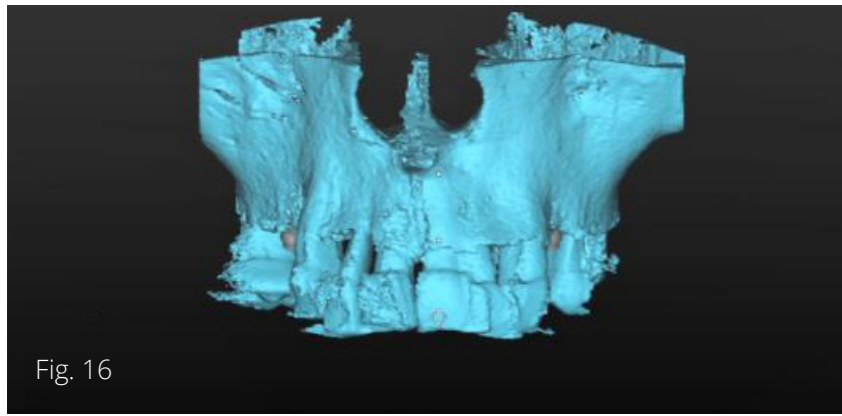
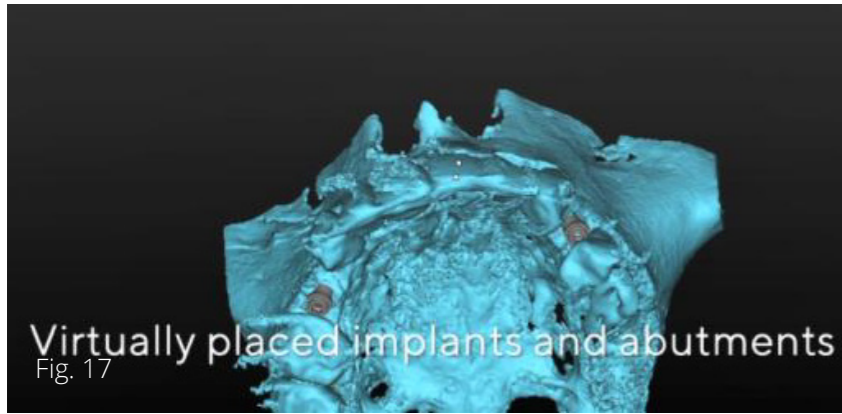

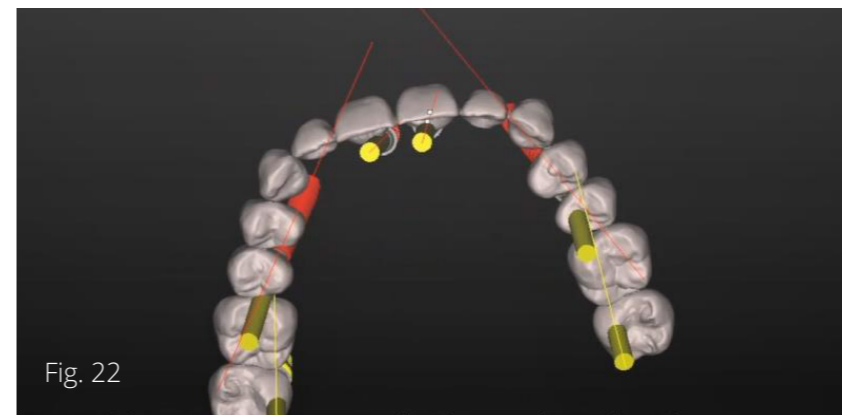
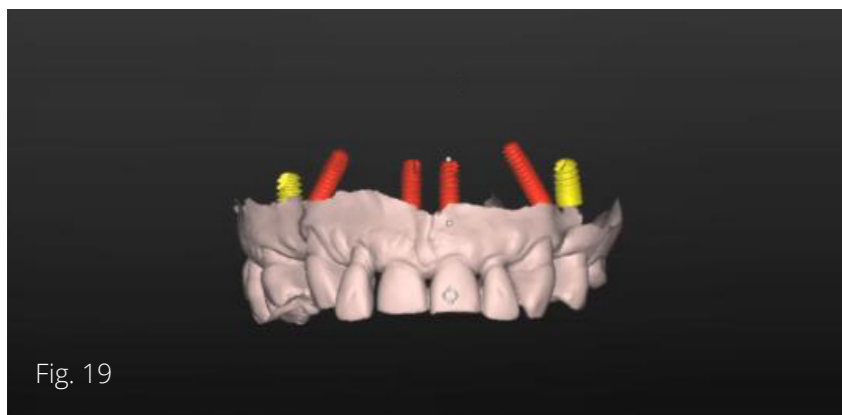
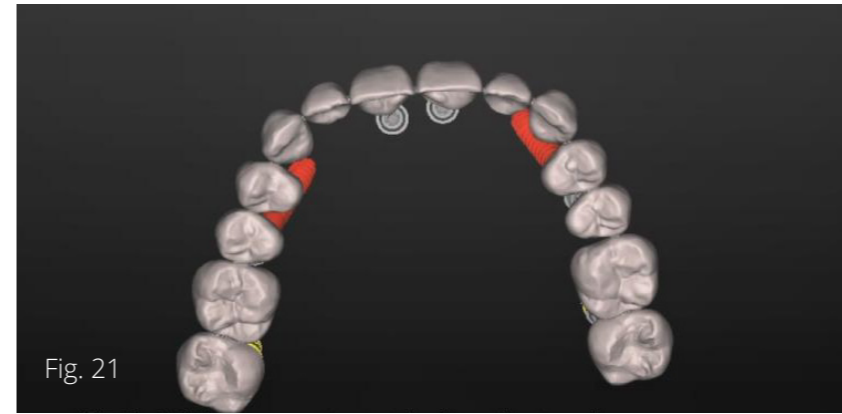
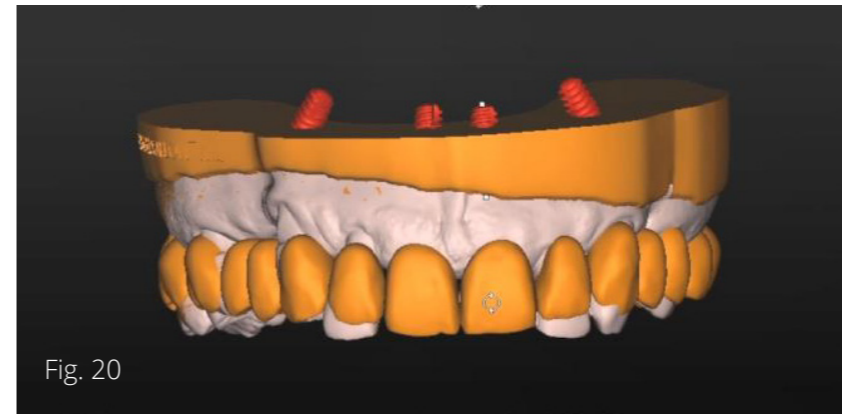
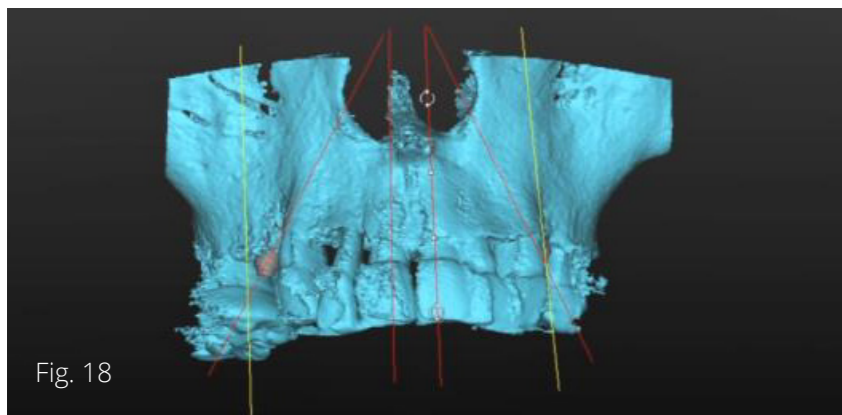


Fig. 16 - 24
The digital wax-up, the CBCT scan and the intraoral image were then imported into Simplant software, which was used to create an accurate guided surgery plan.



During this process, six Ankylos C/X dental implants and Balance Base abutments from Dentsply Sirona were planned for virtually, which enabled us to verify the ideal angulation of the abutments before implant surgery began.



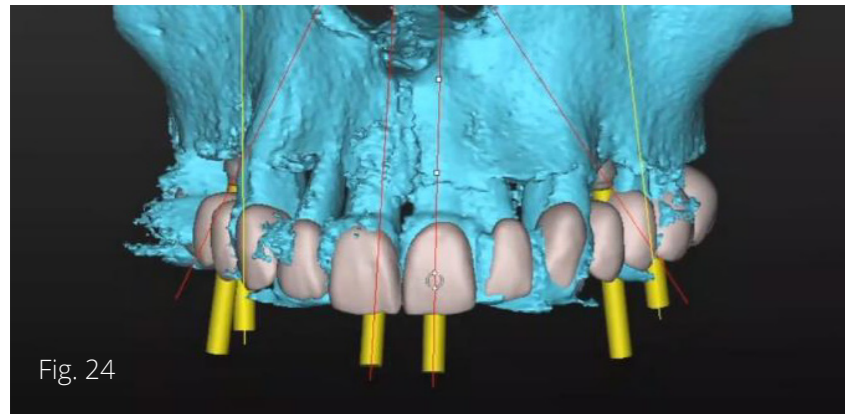


Fig. 24

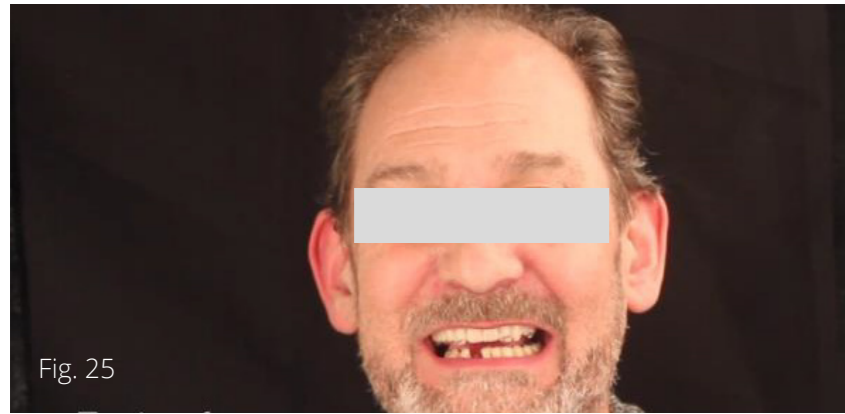

Fig. 25

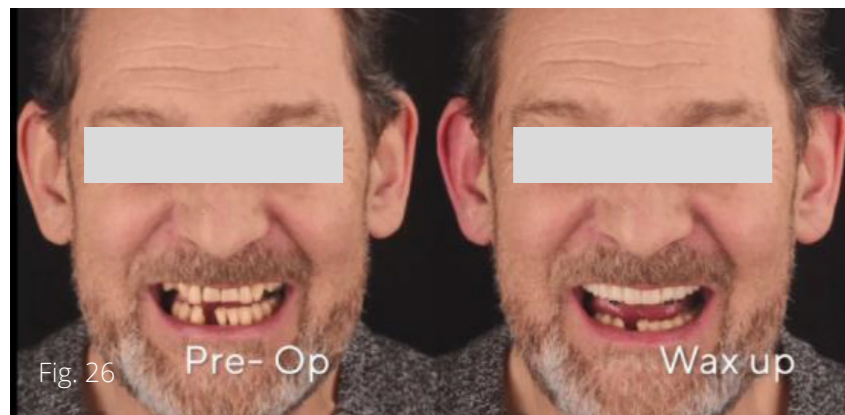


Fig. 26

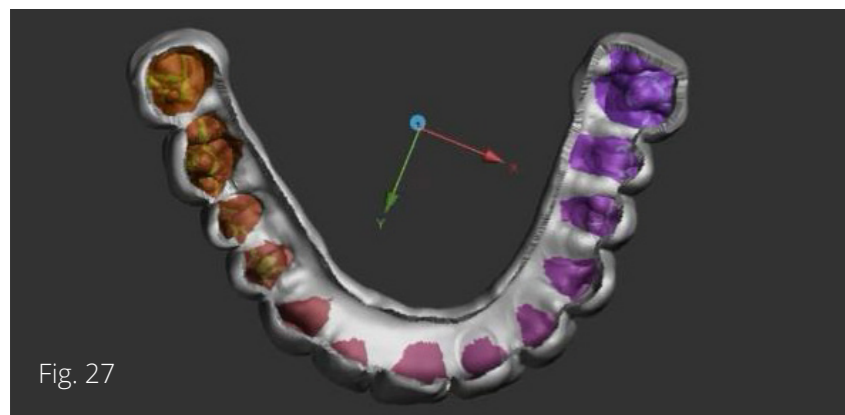


Fig. 27

Fig. 25 - 26

In order to obtain the patient's consent to surgery, a mock-up of the digital wax-up was tried in the patient's mouth, which enabled him to see what the final result would look like. Any adjustments to the digital wax-up design could be made at this stage.

Fig. 27 - 30

A prosthetic shell based on the digital wax up was designed in exocad by dental technician, Steve Campbell, and printed out of MFH (micro filled hybrid) material using a NextDent 3D printer.

The exact shape of the digital wax-up could be best achieved using a 3D printer, as opposed to other methods of manufacturing.

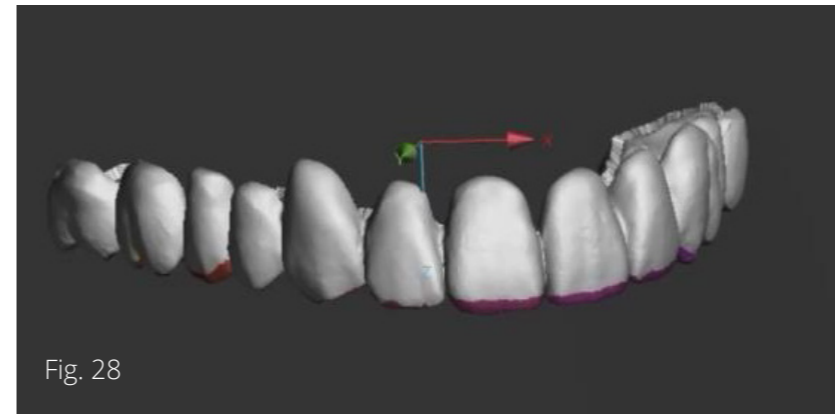


Fig. 28




Fig. 29

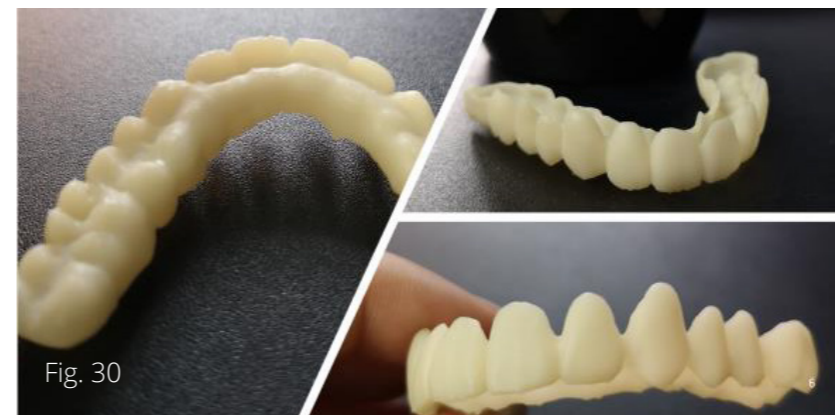

Fig. 30

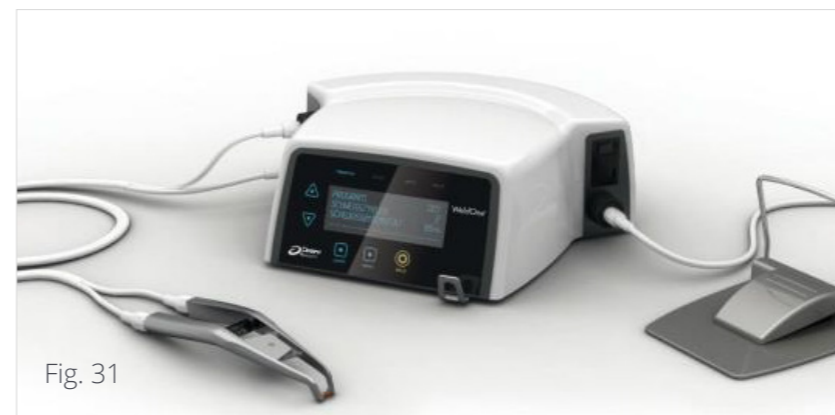

Fig. 31

Fig. 31: Implant placement

After planning the implant and abutment positions in the Simplant software, the surgical guide was made. Surgery began with extraction of some of the teeth in order to place the surgical guide. Following this, the rest of the remaining teeth were extracted and six Anyklos C/X dental implants placed across the upper arch in accordance with the surgical guide.

In some areas of the upper arch, there was insufficient soft tissue due to recession in and around some of the teeth that had been extracted. Therefore, a graft was carried out, which involved extracting soft tissue from the tuberosity in the right side of the patient's upper arch.

In addition, a rotated pedical flap was performed around the upper right lateral area. Also around the arch, bone preservation was also carried out using Bio-Oss®.

The challenge was placing the implants at the correct angle so that a good emergence profile would develop. The patient's sinuses were also relatively low, which is why long, angled implants were placed and angled distally. If these implants had not been selected, it would not be possible to place the implants in these areas. Implant surgery was completed following the placement of the 3D-printed prosthetic shell.

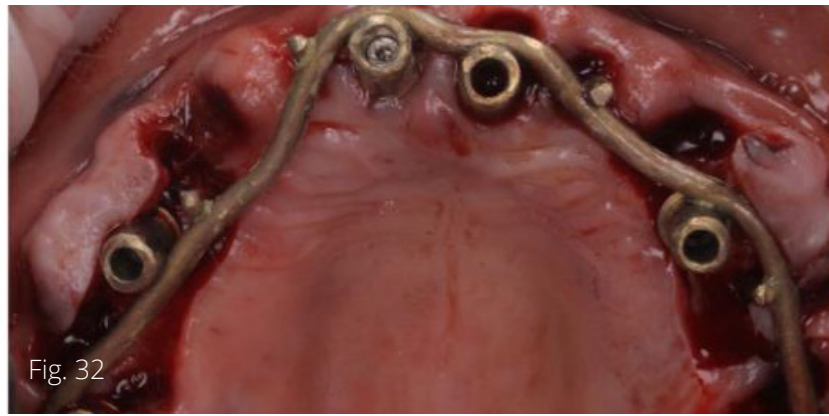
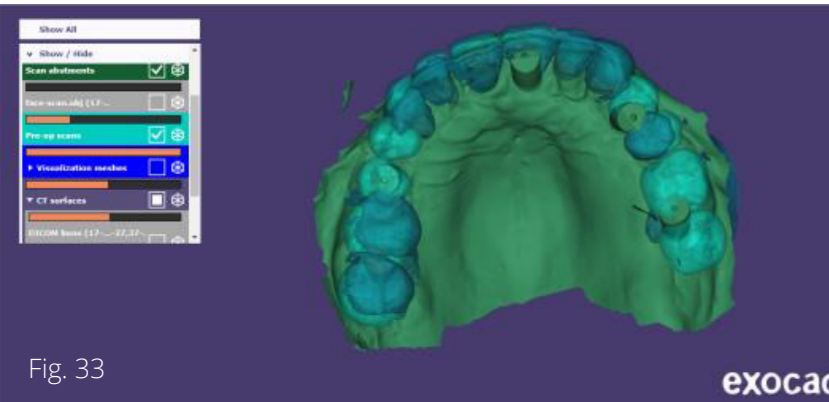


Fig. 32
The WeldOne™ protocol by Dentsply Sirona was followed. This involved attaching WeldOne™ abutments to the implants, and then welding a framework intraorally with wire.



Implant restoration
After an appropriate period of healing, the patient returned to the practice for the restorative phase of the treatment.

Fig. 33 – 38
The 3Shape TRIOS was used to take another intraoral scan with six Elos Accurate® Scan Bodies and Balance Base abutments in place. The intraoral scan was then imported into exocad, where it was combined with the DSD and the patient-approved digital wax-up created at the beginning of treatment. The dental laboratory needed to ensure that these scans were aligned correctly in order to design an accurate provisional bridge. Otherwise, the restoration would have resulted in an incorrect occlusal cantilever or position. The digital design of the provisional bridge was positioned over the scan flag arch within the exocad software. This was then verified with the patient's 3D face scan to ensure the restoration would be correctly aligned.

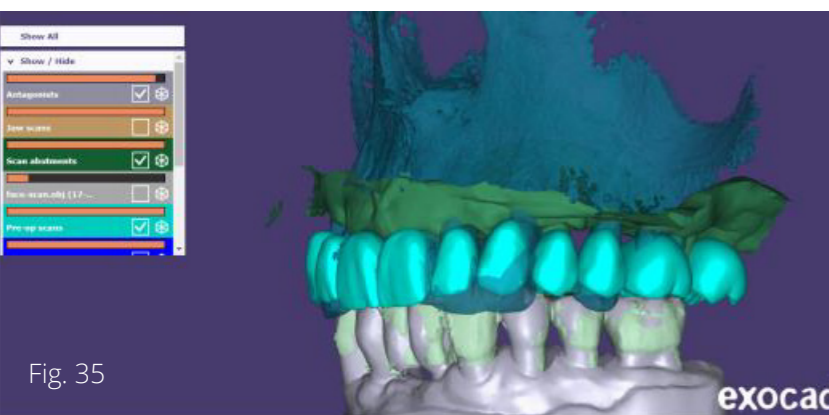
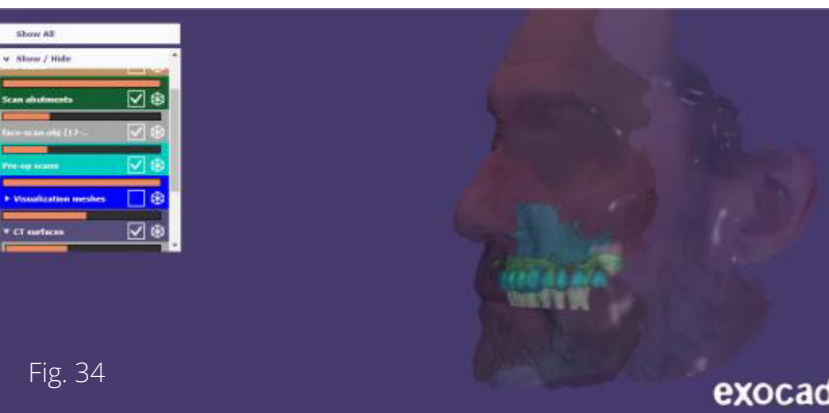


Fig. 35
Demonstrates the position of the provisional bridge would be in once it was fitted. The lab made sure the prosthesis would emerge from the soft tissue correctly using the intraoral scan of the Elos Accurate® Scan Bodies.

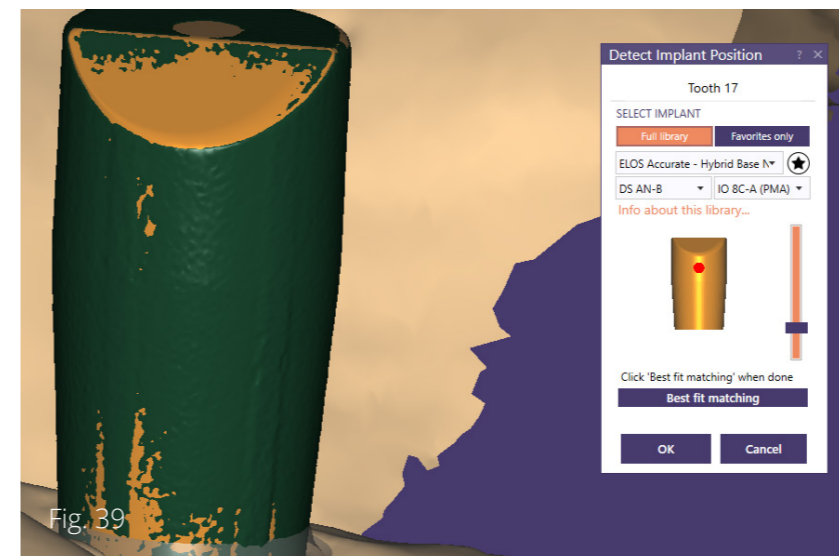


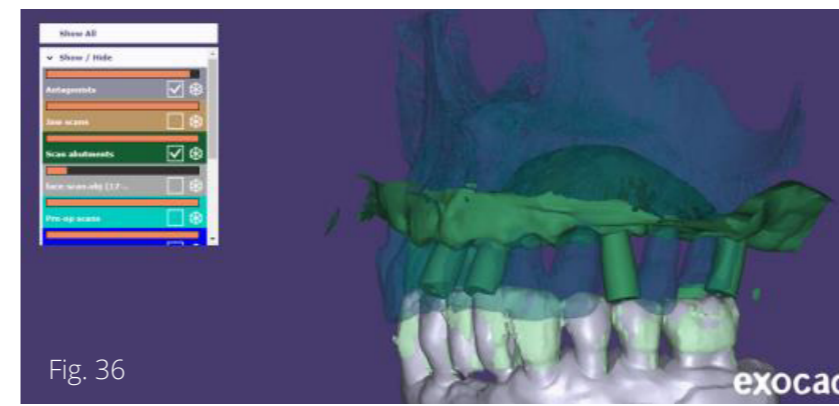


Fig. 37 - 40
The digital impression was aligned with the Elos Accurate® Scan Body using the Elos Accurate® Hybrid Base Non-Engaging library to ensure the ideal fit for the restoration.



Fig. 40

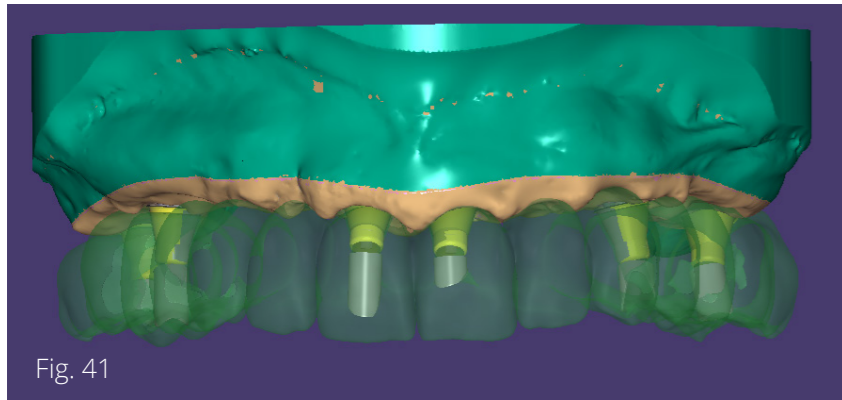


Fig. 41

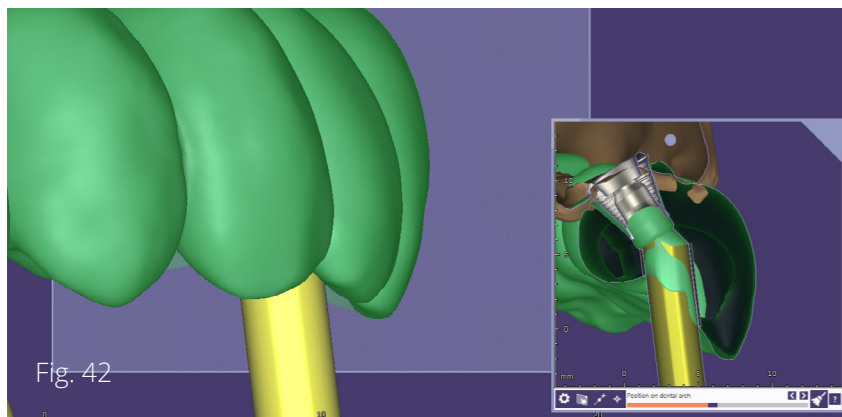


Fig. 42

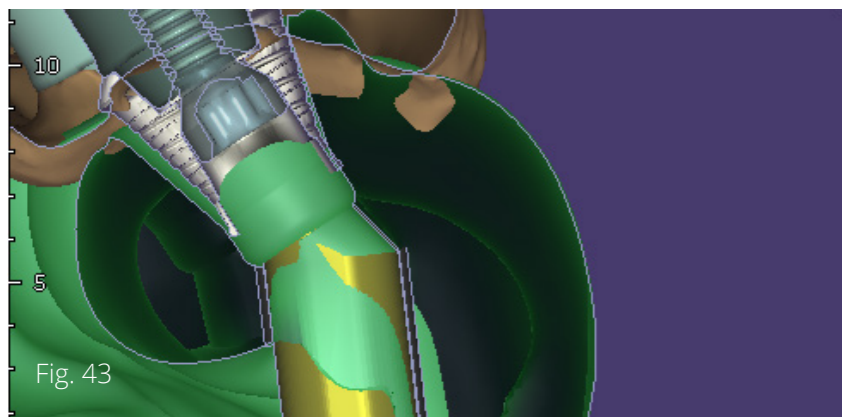

Fig. 43

Fig. 41 - 43
This process shows the CAD design of the bridge with the angulation of the screw channel that was needed to ensure an aesthetic result for the patient.

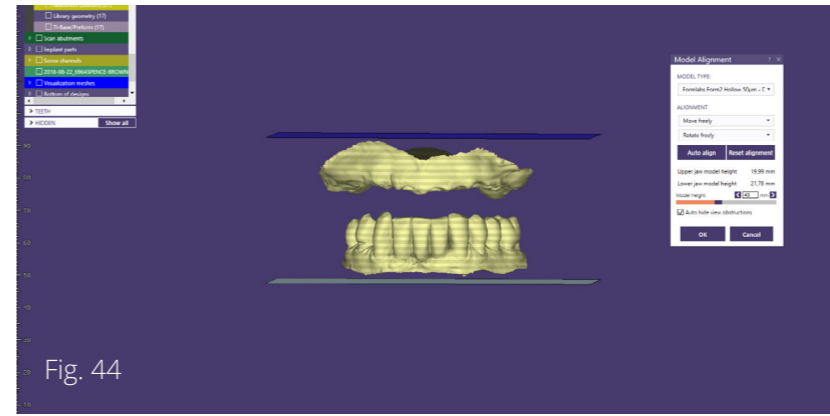


Fig. 44




Fig. 45

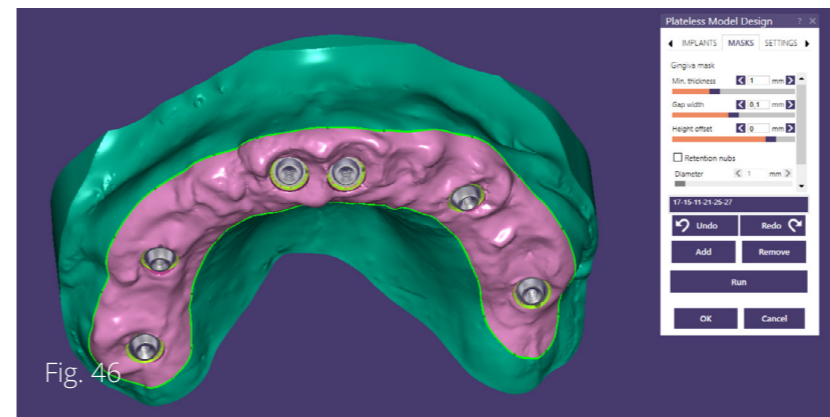


Fig. 46

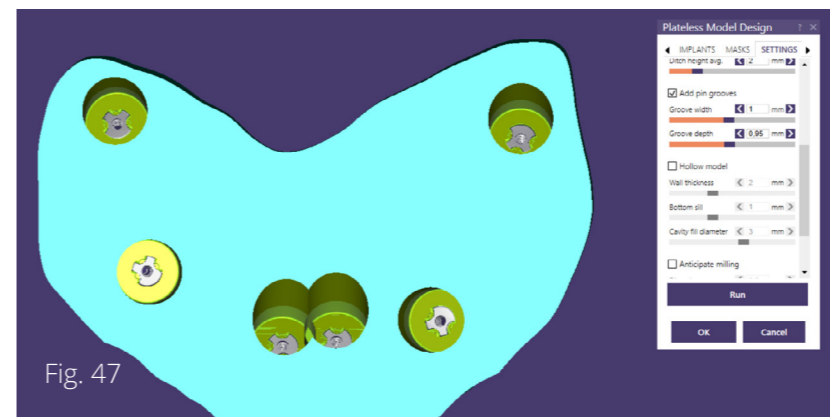


Fig. 47

Fig. 44 - 47
In the Model Creator software, a model was designed using the Elos Accurate® Analog for Printed Models.

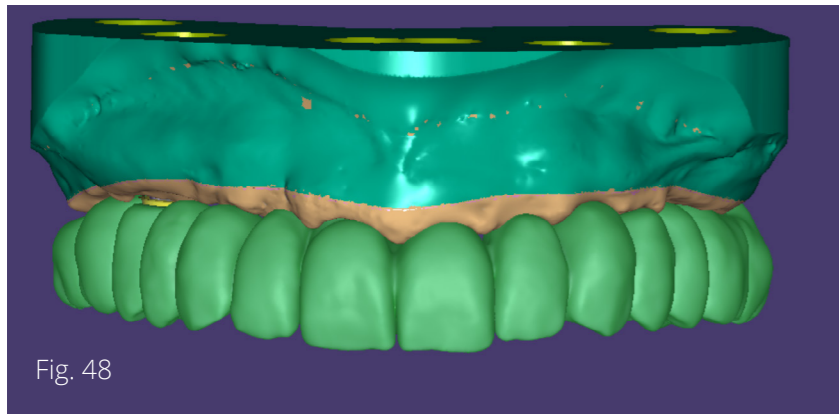


Fig. 48

Fig. 48 - 51

This process shows the final CAD design and CAD output of the screw retained bridge and model with the Elos Accurate® Analog for Printed Models.

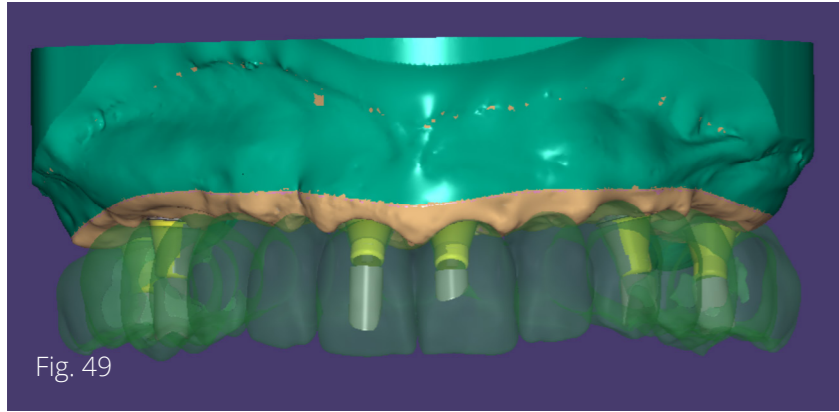


Fig. 49

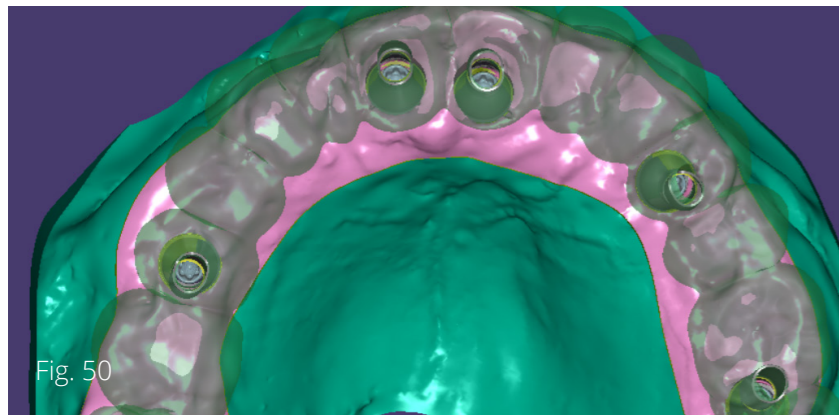


Fig. 50

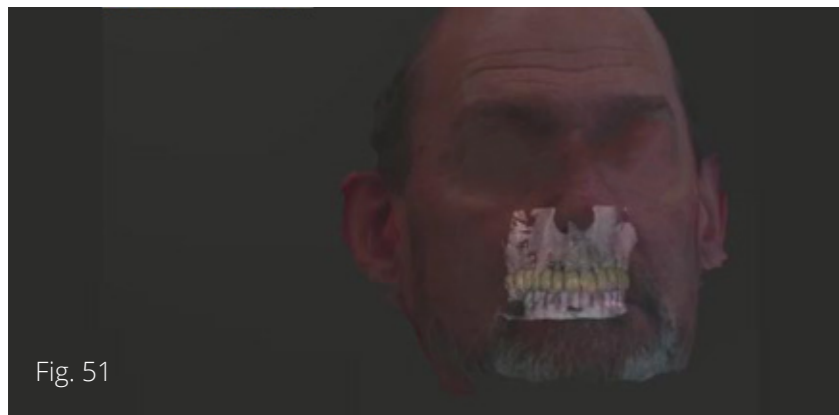


Fig. 51

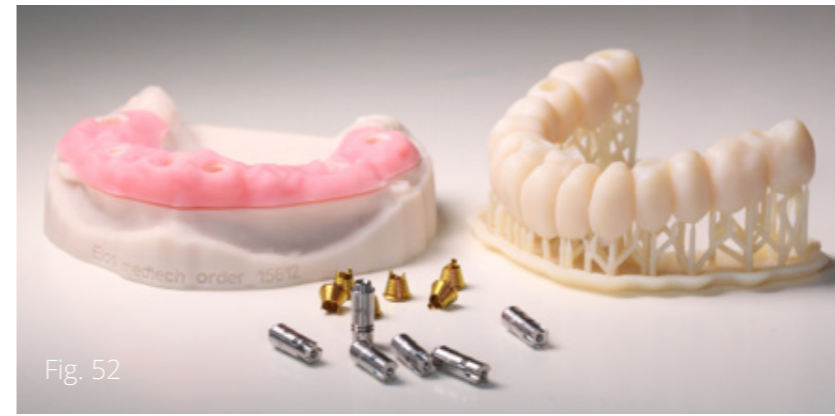

Fig. 52

Fig. 52 - 53

Printed try-in and temporary bridge with Elos Accurate® Hybrid Base™ Non-Engaging made using the NextDent 5100 3D printer with the MFH (micro filled hybrid) material from NextDent.

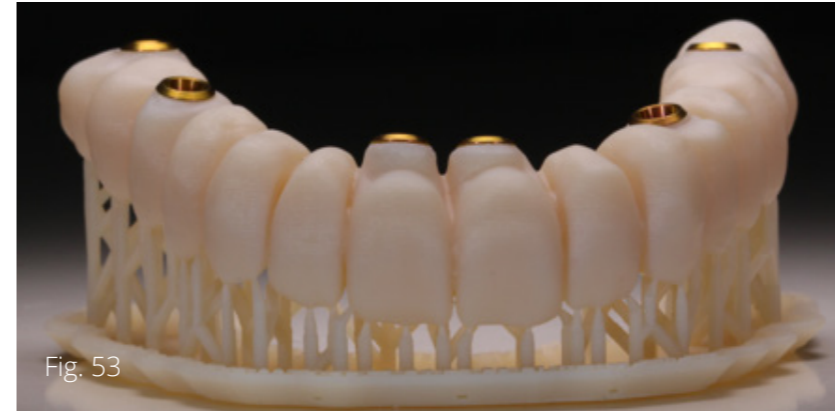


Fig. 53



Fig. 54

Fig. 54 - 57

The model was printed with a Carbon® printer. The Elos Accurate® Analog for Printed Models were placed by using the installation tools Elos Accurate® Analog Pliers, Elos Accurate® Analog Insertion Pin and Elos Accurate® Analog Insertion Screw. A guide for the PMA installation procedure can be found here.



Fig. 55



Fig. 56

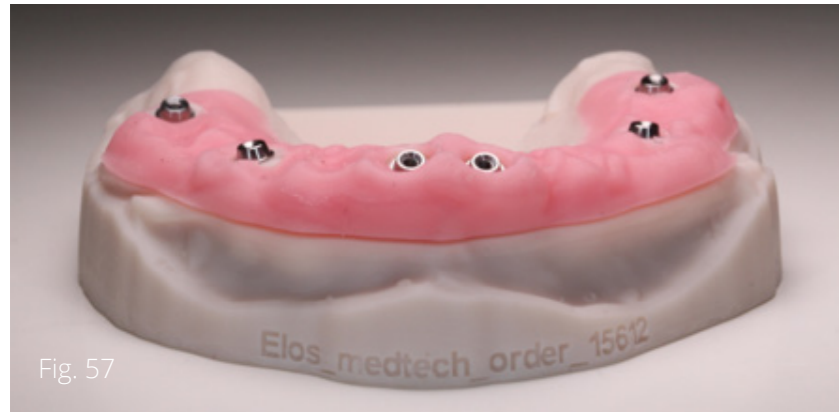

Fig. 57

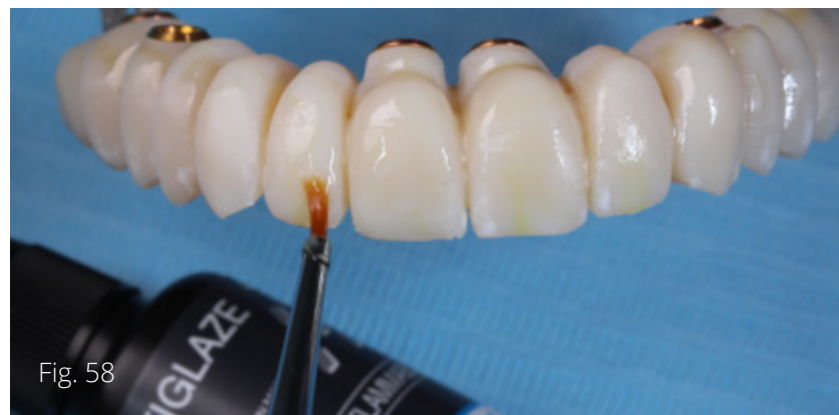

Fig. 58

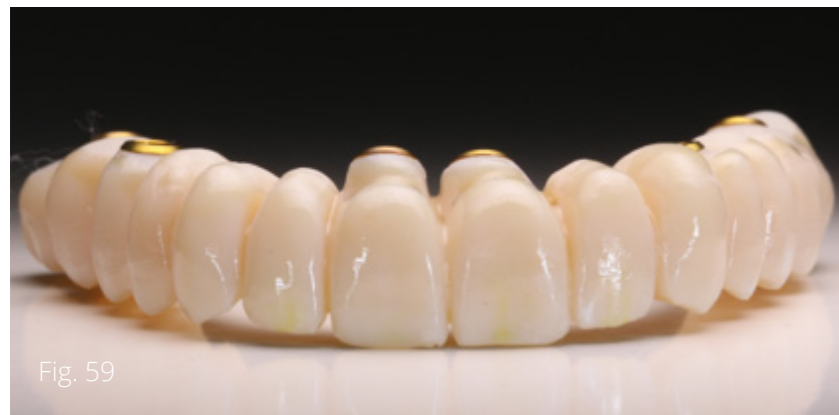

Fig. 59

Fig. 58 - 59

The printed bridge was coloured and glazed with GC stains and Opti glaze for the aesthetic result during the temporisation. The temporisation bridge was used as a verification bridge for the patient.

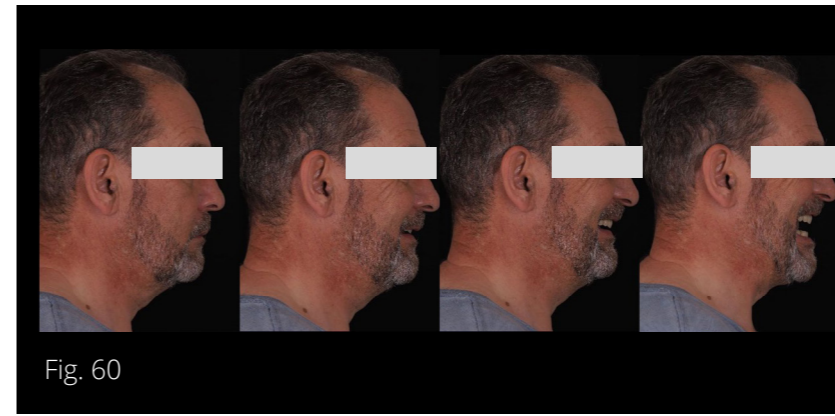


Fig. 60

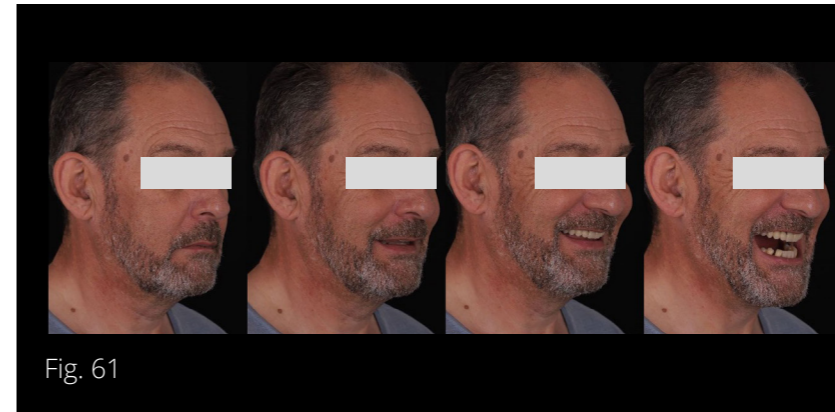

Fig. 61

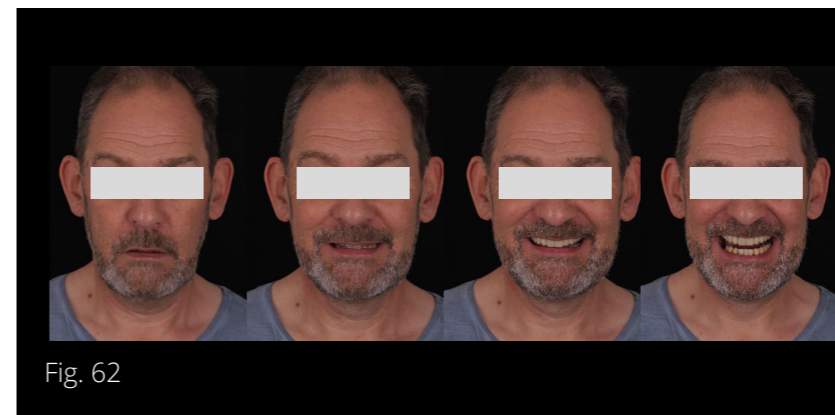

Fig. 62

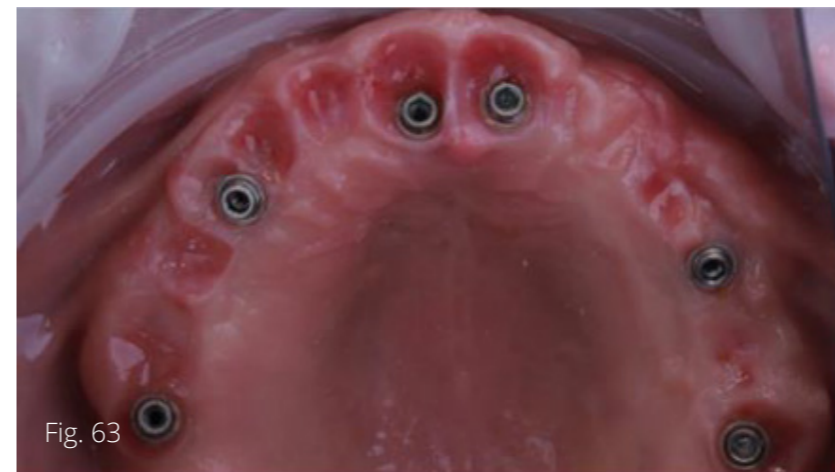

Fig. 63

Fig. 60 - 67

Here, a provisional PMMA bridge was milled, which was built around six Elos Accurate® Hybrid Base™ Non-Engaging cylinders that were placed into the PMMA that mirrored the shape of the wax up and the scan body positions from fig. 48.

Before it was fitted, the provisional bridge was tried in the patient's mouth to ensure that the occlusal cantilever was correct and that the soft tissue contact had been achieved. The temporary restoration was left in the mouth for two months.

The temporary bridge managed the soft tissue effectively for the final stage of treatment. A permanent monolithic zirconia bridge was then designed around six Elos Accurate® Hybrid Base™ Non-Engaging cylinders milled and finished by Uniqa Dental Laboratory, and cemented to the Elos Accurate® Hybrid Base abutments intraorally.

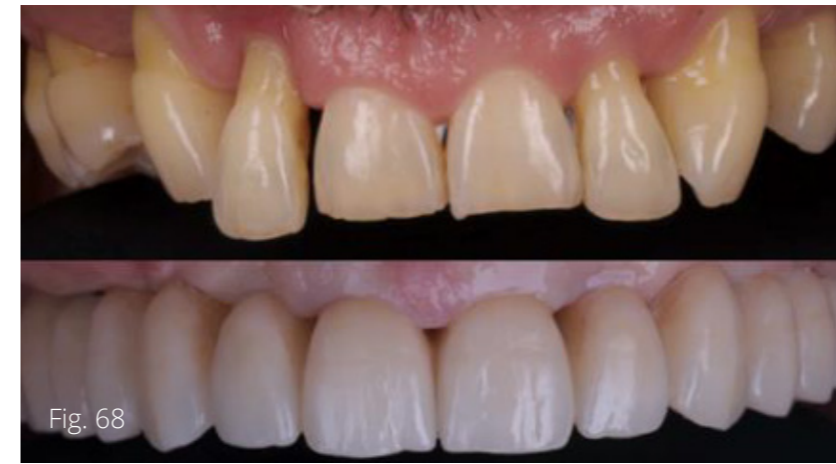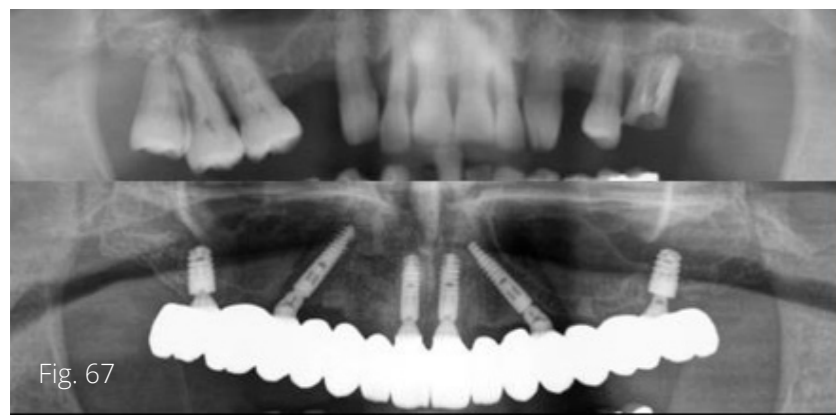

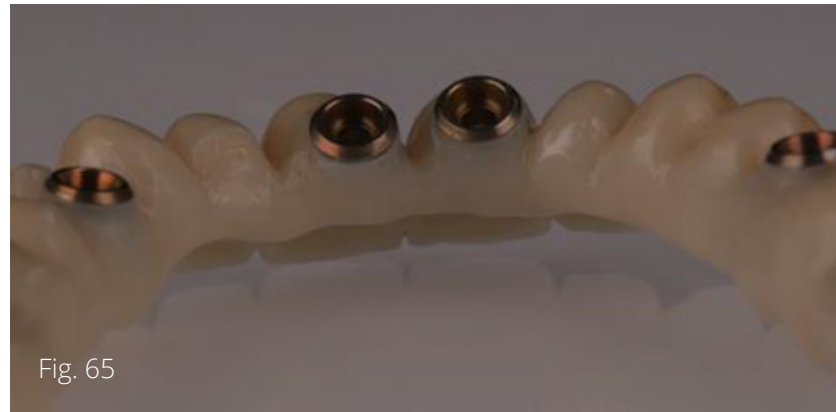
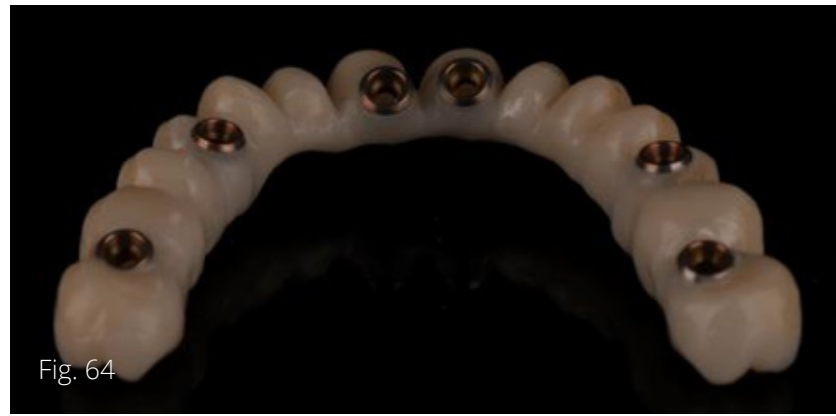
Fig. 68
The final result with the emergence of the permanent restoration from the soft tissue. The patient was very happy with the overall outcome.

Review

In this case, the digital workflow enabled us to design the ideal implant restoration based on the patient's facial profile. We were able to use this design throughout the treatment process, from implant surgery to the final restorative stage. Although multiple technicians were involved in this case, we were still able to deliver the same result that was accepted by the patient at the beginning of treatment during the try-in of the mock-up.

Another advantage of a fully digital workflow in this case was the fact that at no point did the patient have an analogue impression taken. The digital impression facilitated better communication between the treating clinicians and allowed us to achieve the best result.

The other advantage of this digital workflow was afforded by the [Elos Accurate® Scan Bodies](#), which enabled us to consistently produce highly accurate provisional and permanent restorations. This case ultimately shows how a digital workflow can ensure a patient-approved implant treatment experience from beginning to end. It also demonstrates the high quality outcomes that can be achieved with a complete digital workflow, which will eventually become easier, simpler and faster in the years to come.

Thank you for your contribution:

Martin Wanendeya , Ten Dental

Martin Wanendeya graduated from the University of Bristol in 1995. Since 2004 he has been a partner at Ten Dental, an interdisciplinary specialist referral practice in London, where his work is limited to implant and aesthetic dentistry. He is a tutor on the diploma in implant dentistry program at the Royal College of Surgeons, England, having been awarded the diploma at advanced level. He has a special interest on digital implant dentistry and digital smile design and has lectured internationally on all aspects of implant dentistry.



Steven Campbell, Nexus Dental Lab

Steven is a GDC registered dental technician with over 27 years dental experience who owns and manages the multiple location Nexus Dental Lab Network with his highly skilled team of technicians. He has a passion for the life changing service the dental team provide to patients using the latest technologies and digital workflows.



Khristo Ivanov, Uniqa Dental Laboratory

Khristo Ivanov, RDT, founded Uniqa Dental Laboratory in London in 2008 and qualified as a Dental Technician in 1996. He has spent many years in a private laboratory, specialising in implant-supported work and fixed aesthetic cases that include all porcelain restoration and veneers. Khristo participates in numerous education programs within Dental Technology.



About Elos Medtech

Elos Medtech provides turnkey solutions for dental professionals all over the world. We offer dental implant components, instruments and digital libraries for an open digital workflow as well as a well-proven standard prosthetic solution for a traditional workflow to serve the needs of dental professionals. We are one of the world's leading development and production partners for the medtech industry with facilities in Europe, Asia and the United States.

Curious for more? Contact us at dentalsupport@elosmedtech.com or go visit:



elosdental.com
shop.elosmedtech.com
elosmedtech.com

